

the longevity of temporary hemodialysis catheters by insertion site in patients undergoing hemodialysis: systematic review

by Universitas Warmadewa Admin

Submission date: 04-Mar-2024 09:04AM (UTC+0700)

Submission ID: 2310716503

File name: 2023_LongetivityMAP.pdf (623.86K)

Word count: 6273

Character count: 33770

REVIEW

The longevity of temporary hemodialysis catheters by insertion site in patients undergoing hemodialysis: systematic review

I Gusti PUTRA¹, Heroe SOEBROTO^{1*}, Yan E. SEMBIRING¹, Danang H. LIMANTO¹,
Arief R. HAKIM¹, Pande A. PERMATANANDA², Jeffrey J. DILLON^{1,3}, Cheong LIM⁴

¹Department of Thoracic, Cardiac and Vascular Surgery, Faculty of Medicine, Dr. Soetomo General Hospital, Airlangga University, Surabaya, Indonesia; ²Department of Pharmacology, Faculty of Medicine and Health Science, Warmadewa University, Denpasar, Indonesia; ³Department of Cardiothoracic Surgery, Jantung Negara Institute, Kuala Lumpur, Malaysia; ⁴Department of Thoracic and Cardiovascular Surgery, Seoul National University Bundang Hospital, Seongnam, South Korea

*Corresponding author: Heroe Soebroto, Department of Thoracic, Cardiac and Vascular Surgery, Faculty of Medicine, Dr. Soetomo Academic General Hospital, Airlangga University, Surabaya, East Java, Indonesia. E-mail: heroe.soebroto@fk.unair.ac.id

ABSTRACT

Patients with advanced stage chronic kidney disease (CKD) often require hemodialysis as renal replacement therapy. However, the use of temporary non-cuffed, non-tunneled hemodialysis catheters for vascular access is frequently associated with complications. This study aims to evaluate the durability of temporary hemodialysis catheters based on the insertion site in hemodialysis patients. Following the PRISMA Guidelines, we systematically searched electronic reference databases (PubMed, ScienceDirect, and Google Scholar). We included articles published in English between 2000 and 2023 that utilized prospective, retrospective, or cross-sectional observational methods, focusing on the durability of temporary hemodialysis catheters and insertion sites. Our study involved 2076 hemodialysis patients from five populations, with mean ages ranging from 48.7±16.7 to 60.6±16.0 years. The duration of catheter use at the internal jugular vein (IJV) insertion site ranged from 21.6±14.2 days to 36.29 days, while at the subclavian vein insertion site, it ranged from 26.5 days to 46.9 days. For the femoral vein insertion site, the duration ranged from 16.4±12.1 days to 33 days. The results indicated that both the IJV and subclavian vein insertion sites exhibited greater durability compared to the femoral vein. Furthermore, complications associated with the femoral vein insertion site were significantly more common in cases involving temporary hemodialysis catheters. However, additional studies are needed to comprehensively assess the durability of temporary hemodialysis catheters based on insertion site in hemodialysis patients. The authors declare no competing interests, and no funding was provided for this study.

(Cite this article as: Putra IG, Soebroto H, Sembiring YE, Limanto DH, Hakim AR, Permatananda PA, *et al*. The longevity of temporary hemodialysis catheters by insertion site in patients undergoing hemodialysis: systematic review. *Ital J Vasc Endovasc Surg* 2023;30:100-6. DOI: 10.23736/S1824-4777.23.01600-5)

KEY WORDS: Prosthesis failure; Renal dialysis; Catheters.

A non-communicable illness, chronic kidney disease (CKD) is still a major public health concern in Indonesia and its prevalence is rising. CKD is an emerging public health issue globally and its burden is growing rapidly around the world.¹ In South Asia, the pooled prevalence of CKD among the general population was 14%.² Patients with CKD frequently present to medical institutions in advanced or severe stages, necessitating

hemodialysis as renal support or renal replacement treatment.^{3, 4} According to patient characteristics, CKD is most prevalent in people aged 65 to 74 (82.3%), in people who have never attended school or have not yet done so (57.3%), and in people who are not employed (47.6%). It is also more prevalent in men than in women (41.7%) and in urban areas (38.5%) compared to rural ones (38.4%). Patients from DKI Jakarta Province (38,7%) make up the

majority of CKD patients who have or are receiving hemodialysis.⁵

Hemodialysis treatment is widely used as renal support or renal replacement therapy for cases of kidney disease, especially end-stage renal disease (ESRD).³ Hemodialysis for patients with ESRD can be performed using an arteriovenous fistula (AVF) or catheter.^{3, 6} According to the annual statistics of the United States Renal Data System, as many as 62.6% of dialysis patients use a catheter and as many as 16% of dialysis patients use an AVF as a vascular access for their first hemodialysis, while as many as 81% of patients use a dialysis catheter as a vascular access while receiving hemodialysis or waiting for AVF maturation.⁶ There are two types used as hemodialysis catheter, that are tunneled dialysis catheter (TDC) and non-NTDC.² Most patients who require long-term renal replacement therapy will receive hemodialysis with a tunneled hemodialysis catheter (dual/double-lumen) as Putra *et al.* found in their literature that TDC is better than NTDC because NTDC have higher risk for infection than TDC.² A study found that compared to NTDCs, TDCs for patients with acute kidney injury requiring renal replacement therapy had improved renal replacement delivery and fewer mechanical complications.⁷ Another study found that the use of a tunneled permanent catheter as temporary vascular access in arteriovenous graft patients improved long-term patency.⁸

Types of catheters that can be used for hemodialysis are permanent and temporary catheters (non-tunneled hemodialysis catheter, NTHC). The use of permanent catheters should be prioritized for patients who need vascular access for more than 1 month.⁴ The vascular access provided must be adequate to support the effective management of hemodialysis.³ However, catheter use is associated with an increased risk of death mostly due to catheter-related infections (CRI).^{6, 9} CRI has increased the duration of hospital stay from 2.4 to 5.7 days followed by increased mortality. CRI is responsible for 15%-36% of all hemodialysis patients' deaths and 20% of total hospitalizations.³

Non-cuffed, NTHCs are often used as temporary vascular access in hemodialysis patients, but complications associated with their use are common. One of the most important complications is infection with rates as high as 10.3-50% at 2 months of use.^{3, 10, 11} Long-term use, recent CRI history, recent surgery, diabetes mellitus, and iron overload are all factors that might contribute to catheter infection. Gram-positive bacteria frequently cause recurrent illnesses. Gram-positive bacteria including *Staphylococcus aureus* are responsible for up to 40-81% of ill-

nesses. Methicillin-resistant *A. aureus* is a serious bacteria that can cause infections in hemodialysis patients. Other issues include thrombosis, catheter fibrin sheathing, extrusion and kinking, and torsion have caused problems and failures with catheter placement.^{3, 6, 10-12}

Temporary catheters should not be used for longer than 5-7 days in the femoral vein and 2-3 weeks in the IJV and subclavian vein, per the National Kidney Foundation-Dialysis Outcomes Quality Initiative (NKF-DOQI) recommendations, which are based on the cumulative risk of bacteremia.^{3, 10, 11} In ideal circumstances, temporary catheters should only be used briefly for urgent or acute problems in order to prepare access to permanent hemodialysis.³ Temporary femoral vein catheterization can be performed in patients with pulmonary oedema and serious hyperkalemia.⁴ Insertion of the femoral vein is relatively quick and easy to perform, but arterial puncture and infection are common complications (hence, the National Kidney Foundation recommended a real-time ultrasound to guide the insertion of central venous catheters in order to increase the success rate of placements). In addition, insertion of the jugular vein (first choice of catheter insertion in the right IJV and second choice in the left internal jugular vein) should be preferred over insertion of the subclavian vein because subclavian catheters can increase the occurrence of central venous stenosis and subclavian vein thrombosis.^{10, 11, 13, 14}

Even though it is well recognized that using temporary catheters for longer than is necessary can lead to a number of difficulties, many nations, including Indonesia, continue to do so. In Brazil, according to research done by Bonfante *et al.* between 2000 and 2004, 18.2% of patients were still utilizing temporary hemodialysis catheters for more than 3 months.¹⁵

There are many factors that play a role in determining the durability of the hemodialysis catheter. Based on research conducted by Wang *et al.* in China in 2014, age, diabetes mellitus, education level, place of residence, the absence of permanent vascular access pre-hemodialysis, the absence of drugs to prevent thrombus formation in the catheter (causing catheter blockage due to the accumulation of fibrin and clot formation at the cannula access site which can be identified by symptoms such as the impossibility of fluid injection and no blood return), NTHC catheter type, hemoglobin level, skin preparation method, and catheter insertion location affect the durability of a catheter. A study conducted by Develter *et al.* in Belgium dem-

onstrated that catheter insertion in the IJV was a strong predictor of better infection resistance and longer durability than in other locations.^{9, 12}

Methods

Eligibility criteria

Inclusion criteria for those studies are as follows:

- published in English, and full-text was available;
- published between January 2000 and January 2023;
- the studies were prospective, retrospective, and cross-sectional observational studies;
- the studies that assessed the durability of temporary hemodialysis catheter by insertion site in hemodialysis patients.

Guidelines

We used the Preferred Reporting Items for Systematic Reviews and Meta-Analysis (PRISMA) Guideline to perform the reporting of this study. We can find 5 appropriate studies included in the review, as shown in the flow diagram in Figure 1.

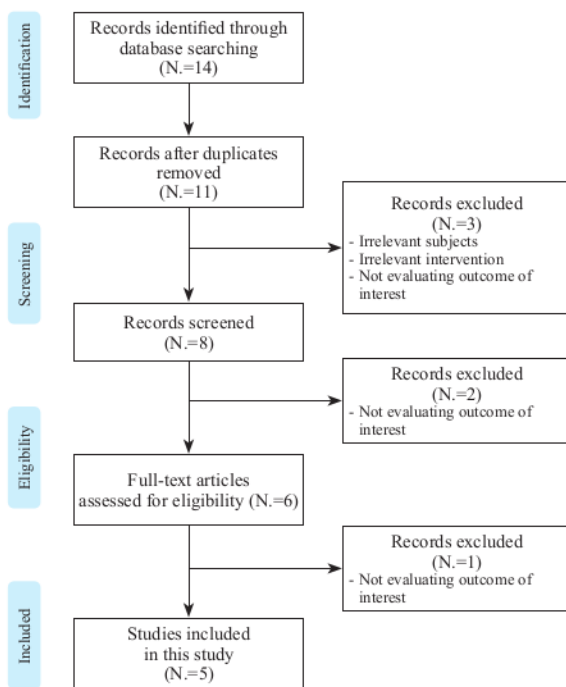


Figure 1.—PRISMA flow diagram.

Search strategy

We performed a systematic search on PubMed, ScienceDirect, and Google Scholar, following PRISMA guidelines. The search was conducted on April 1st, 2023, using the search terms durability, temporary hemodialysis catheter, and combination of the terms.

Data extraction and assessment

The key outcome measure was the durability of the hemodialysis catheter, assessed by the length of days which the catheter might function well in the patients' body. Several causes may affect the durability of the hemodialysis catheter, such as puncture site hemorrhage, hematoma, artery puncture, infection, lumen thrombosis, kinking of the catheter, and other dysfunctions.^{3, 4, 6, 9, 11}

Results

Study characteristics

In this systematic review, we found in total of five studies, including two prospective studies, two cross-sectional studies, and a retrospective study related to durability of the temporal hemodialysis catheter and the insertion sites. The length of days or the time the catheter dwell in the insertion site is assessed in three of the studies included, whereas the rest of the studies assessed by the complication emerged. The mean age of patients is in the range of 48.7±16.7 to 60.6±16.0 years.

Insertion sites

Insertion sites in studies included in this systematic review divided into three groups, internal jugular vein, subclavian vein, and femoral vein. However, the percentage of the insertion sites in each studies weren't equals. The insertion of IJV site ranged from 44.3% to 75.3%. The insertion of subclavian vein site ranged from 1.2% to 48.4%. The insertion of femoral vein site ranged from 7.4% to 38.3%.

Duration of insertion

The durability of the temporal hemodialysis catheter by its insertion sites is assessed by the duration of insertion. The mean duration of IJV insertion site ranged from 21.6±14.2 days to 36.29 days. The mean duration of subclavian vein insertion site ranged from 26.5 days to 46.9 days. The duration of femoral vein insertion site ranged from 16.4±12.1 days to 33 days (Table I).

This document is protected by international copyright laws. No additional reproduction is authorized. It is permitted for personal use to download and save only one file and print only one copy of this Article. It is not permitted to make additional copies (either sporadically or systematically, either printed or electronic) of the Article for any purpose. It is not permitted to distribute the electronic copy of the Article through online internet and/or intranet file sharing systems, electronic mailing or any other means which may allow access to the Article. The use of all or any part of the Article for any Commercial Use is not permitted. The production of derivative works from the Article is not permitted. It is not permitted to remove, cover, overlay, obscure, block, or change any copyright notices or terms of use which the Publisher may post on the Article. It is not permitted to frame or use framing techniques to enclose any trademark, logo, or other proprietary information of the Publisher.

TABLE I.—*Studies characteristics*.^{3, 6, 9-11}

| Author | Study Design | Population; age (mean±SD; year) | Insertion site(s) | Duration of insertion (days) | Outcome of catheterization | Discussion |
|--|-----------------|--|--|--|---|---|
| 1 Naumovic <i>et al.</i> ¹¹ (Serbia 2004) | Prospective | Jugular group: 48.7±16.7; femoral group: 52.8±16.5 | Internal jugular vein (61.7%) and femoral vein (38.3%) | Jugular group: 21.6±14.2; femoral group: 16.4±12.1 | Comparison between femoral vs. jugular: early puncture site hemorrhage (NS); hematoma (NS); Artery puncture (NS); late lumen thrombosis (P<0.005); extrusion and kinking (NS) | Overall durability of catheterization according to their tip locations (femoral vs. jugular) did not show any significant difference (P>0.005); however, lumen thrombosis was commonly seen among femoral catheter (P<0.005) |
| 2 Bara <i>et al.</i> ³ (Indonesia, 2022) | Prospective | 74 study samples (64.5% male, 35.5% female); mean (range): 47.27 (18-74) | IJV (48.6%), subclavian (37.8%), femoral (13.5%) | IJV (mean=36.29) subclavian (mean=46.9), femoral (mean=33) | Average durability between two groups: P=0.362 | No significant difference in terms of catheter durability among three sites observed (P=0.362), although Kaplan-Meier survival curve showed higher survival rate among patients that underwent catheterization at the subclavian vein compared with the other sites |
| 3 Nasiri <i>et al.</i> ⁹ (Iran, 2022) | Cross sectional | 122 patients (male 51%, female 49%), 58.9±16.4 | Subclavian (48.4%), jugular (44.3%), femoral (7.4%) | NA | Average durability between two groups: P>0.05 (NS) | This study indicates that no durability difference between subclavian, IJV, dan femoral catheterization |
| 4 Wang <i>et al.</i> ⁶ (China, 2015) | Cross sectional | 865 patients (male 57.2%, female 42.8%); 49.53±18.42 | Subclavian, IJV, femoral | Mean=26.5 months | Comparison between three groups: Catheter infection: P=0.227; catheter dysfunction: P<0.001; central vein stenosis: P=0.110. | Higher dysfunction rate of the catheter insertion site was significantly higher among patients who had underwent femoral vein catheterization if compared by the subclavian, internal and external jugular vein |
| 5 Aydin <i>et al.</i> ¹⁰ (Türkiye, 2012) | Retrospective | 908 patients (47.1% female, 52.9% male); 60.6±16.0 | IJV (75.3%), femoral (23.5%), subclavian (1.2%) | NA | Comparison of arterial puncture: higher in femoral catheterization (P<0.001) | Specifically, the complication rate of catheterization in the first 6 months was significantly higher among femoral group than in jugular or subclavian group |

Discussion

This study contains 2076 hemodialysis patients to evaluate the durability of temporary hemodialysis catheter by the insertion site, in total of five different populations. Our systematic review found that there were several causes affected the durability of the hemodialysis catheter, such as puncture site hemorrhage, hematoma, artery puncture, infection, lumen thrombosis, kinking of the catheter, and other dysfunctions. In general, temporal hemodialysis catheters are inserted into a large vein in the body. The articles included in this systematic review included three insertion sites of the hemodialysis catheter.^{3, 4, 6, 9, 11}

In a prospective research, Naumovic *et al.* discovered that the IJV insertion site had superior temporal hemodi-

alysis catheter longevity than the other insertion sites, as measured by the length of time the catheter was used. This might be caused by IJV has a relatively large diameter, 8-12 millimeters in adults, and its path is straight. This large size allows for the placement of a larger catheter, which in turn allows for faster blood flow rates and more efficient hemodialysis.^{11, 16}

A significant vein in the neck that carries blood away from the head, neck, and upper chest is called the IJV. The IJV is the preferable location for the insertion of a temporal hemodialysis catheter for a number of reasons. IJV catheter insertion is simple due to the IJV's location in the neck. This accessibility may be crucial for severely sick patients who need hemodialysis right away. In these circumstances, it is possible to immediately reach the IJV without

This document is protected by international copyright laws. No additional reproduction is authorized. It is permitted for personal use to download and save only one file and print only one copy of this Article. It is not permitted to make additional copies (either sporadically or systematically, either printed or electronic) of the Article for any purpose. It is not permitted to distribute the electronic copy of the Article through online internet and/or intranet file sharing systems, electronic mailing or any other means which may allow access to the Article. The use of all or any part of the Article for any Commercial Use is not permitted. The production of derivative works from the Article is not permitted. It is not permitted to remove, cover, overlay, obscure, block, or change any copyright notices or terms of use which the Publisher may post on the Article. It is not permitted to frame or use framing techniques to enclose any trademark, logo, or other proprietary information of the Publisher.

substantial dissection or the use of imaging methods like ultrasonography. Furthermore, IJV travels in a straight line to the superior vena cava (SVC). A catheter can be placed into the IJV and then progressed directly into the right atrium and SVC. When a catheter is put into a vein that has a tortuous or twisting route, it increases the chance of catheter-related issues including kinking or migration, which can happen. Moreover, the IJV has a relatively short distance to the SVC, which means that the catheter can be inserted with a lower risk of complications compared to other veins in the neck. For example, the subclavian vein, which is another common site for catheter insertion, has a longer path to the SVC and is more prone to complications such as pneumothorax or hemothorax. However, there are also some disadvantages associated with using the IJV for temporal hemodialysis catheter insertion, such as the risk of carotid artery puncture. The carotid artery is located adjacent to the IJV, and if the catheter is advanced too far, it can puncture the artery and cause bleeding. Another disadvantage of using the IJV for catheter insertion is the risk of damage to surrounding structures such as the thoracic duct or the brachial plexus.^{13, 16}

However, a different prospective research carried out in Indonesia by Bara *et al.* discovered that the subclavian vein is the location for temporal hemodialysis catheter implantation that is the most lasting. Additionally, the subclavian vein, like the internal jugular vein, is a large central vein that makes it simple to insert a catheter. Additionally, the subclavian vein insertion site, like the IJV insertion site, provides a straight path to the SVC, enabling a smooth catheter insertion process with a reduced chance of problems like kinking or migration.^{9, 16}

The subclavian vein is located in the upper chest area, just below the collarbone, and is easily accessible for medical professionals. The subclavian vein is often favored for central venous access, including emergency and acute care access, and tunneled catheters and subcutaneous ports for chemotherapy, prolonged antimicrobial therapy, and parenteral nutrition.³ The subclavian vein puncture technique uses anatomic landmarks to guide venepuncture and a Seldinger technique to thread a central venous catheter through the subclavian vein and into the superior vena cava.¹⁷ The subclavian vein is accessed using a technique called percutaneous catheterization. This involves using a needle to puncture the skin and underlying tissues, and then threading a catheter through the puncture site and into the vein. The catheter is then guided through the vein and into the heart using imaging techniques such as ultrasound or fluoroscopy.

When inserting a hemodialysis catheter into the subclavian vein, there are several factors that must be taken into consideration. The first factor is the risk of complications associated with the procedure. While subclavian catheterization is generally considered safe, there are potential risks such as bleeding, infection, and damage to nearby structures such as the lungs or blood vessels. Hence, patients have to be monitored for any signs of complications, such as bleeding, infection, hemothorax, pneumothorax, brachial plexus injury, hematoma, subcutaneous emphysema, sepsis, thrombosis, and catheter occlusion.^{16, 18, 19} The incidence rates of central venous catheter complications range from 1% to 20%.¹⁸

Despite the potential risks and limitations associated with the use of the subclavian vein as an insertion site for hemodialysis catheters, it remains a popular choice among medical professionals due to its accessibility and ability to accommodate the flow of blood required for the procedure. As with any medical procedure, however, careful consideration must be given to the individual patient's needs and circumstances to ensure the best possible outcome. The subclavian vein may provide a longer dwell time for the catheter as it is deeper in the body than the internal jugular vein. This can be beneficial for patients who require long-term vascular access. Compared to other sites, the subclavian vein provides a more stable catheter position, which may reduce the risk of catheter dislodgement. On the other hand, the subclavian vein has a higher risk of complications compared to the internal jugular vein. These complications may include pneumothorax, hemothorax, arterial puncture, or nerve injury. Due to the deeper placement of the vein and the need for more extensive dissection and imaging methods, such as ultrasound, the insertion of a catheter into the subclavian vein may take longer than it would in the internal jugular vein.^{16, 20}

There are several studies in this systematic review by Naumovic *et al.*, Wang *et al.*, and Aydin *et al.* that found femoral vein as an insertion site is more likely to have a higher dysfunction and complication rate, unlike the other insertion sites. The femoral catheterization procedure involves the insertion of a catheter into the femoral vein in the groin region. The femoral vein is one of the largest veins in the body, making it a suitable site for catheterization in patients who require hemodialysis. It is not recommended in patients with significant peripheral vascular disease, as the procedure may exacerbate the disease. Patients with femoral artery aneurysms or arteriovenous fistulas in the groin region should also not undergo femoral vein catheterization. In addition, patients with a history

of deep vein thrombosis or pulmonary embolism are at higher risk for catheter-related thrombosis and should be carefully evaluated before undergoing femoral vein catheterization. The procedure is performed under sterile conditions. The patient is placed in the supine position with the leg extended and abducted. The skin over the femoral vein is cleansed with antiseptic solution, and local anesthesia is administered. A small incision is made in the skin, and a guidewire is inserted into the vein under ultrasound guidance. Once the guidewire is in place, a dilator and then the catheter are inserted over the guidewire into the vein. The catheter is then secured in place with sutures or adhesive tape.^{10, 11, 13, 16, 21}

Femoral vein catheterization is associated with several potential complications. The most common complication is catheter-related infection, which can lead to sepsis and death. Other complications include catheter-related thrombosis, bleeding, hematoma formation, nerve injury, and arterial puncture. Patients who undergo femoral vein catheterization should be closely monitored for signs of infection, such as fever, chills, and erythema at the site of catheter insertion. In addition, regular flushing of the catheter with heparinized saline is necessary to prevent thrombus formation. Proper care of the femoral vein catheter is essential to prevent infection and thrombus formation. The catheter should be flushed with heparinized saline before and after each hemodialysis session to maintain patency. The site of catheter insertion should be inspected daily for signs of infection, such as erythema, edema, and drainage. Dressings should be changed as needed, and the site of catheter insertion should be cleaned with antiseptic solution before each dressing change. Patients should be educated on the signs and symptoms of catheter-related infection and instructed to seek medical attention immediately if these symptoms develop.¹⁶

Femoral vein catheterization is a common technique used for temporary vascular access in patients undergoing hemodialysis. It is a suitable site for catheterization in patients with acute kidney injury, severe cardiovascular disease, and those awaiting permanent vascular access placement. However, the procedure is associated with potential complications, including catheter-related infection, thrombosis, bleeding.^{16, 21}

Ultimately, the choice of insertion site for a temporal hemodialysis catheter depends on individual patient factors such as the patient's anatomy, medical history, and previous catheter-related complications. All of the insertion sites, the femoral vein, the internal jugular vein, and the subclavian vein have advantages and disadvantages,

and the decision on which site to use should be made by a healthcare provider after considering all the factors involved.^{16, 22}

Conclusions

This systematic review found that femoral vein catheterization is the most not durable compared to other insertion sites. Hence, we recommend femoral vein to be used as the last option. Also, we recommend subclavian vein and IJV to be the insertion sites of temporal hemodialysis catheter, due to their better durability in the included articles. Moreover, more studies are meant to be included in future studies to evaluate the durability of temporal hemodialysis catheter by their insertion sites.

References

- Shrestha N, Gautam S, Mishra SR, Virani SS, Dhungana RR. Burden of chronic kidney disease in the general population and high-risk groups in South Asia: A systematic review and meta-analysis. *PLoS One* 2021;16:e0258494.
- Putra IG, Soebroto H, Sembiring YE, Tjempakasari A. Patency durability of non-tunneled hemodialysis catheter in adult patients with chronic kidney disease stadium 5 with diabetes mellitus and non-diabetes mellitus. *Ital J Vasc Endovasc Surg* 2023;30:15-9.
- Bara ES, Soebroto H, Winarno DJ. The durability of temporary hemodialysis catheter by insertion sites. *Ital J Vasc Endovasc Surg* 2020;29:148-57.
- Kartika H. Chronic kidney disease and its causes. Ministry of Health Directorate General of Indonesian Health Services; 2022.
- Indonesian Health Ministry. Indonesian Health Research and Development Agency. 2018.
- Wang K, Wang P, Liang X, Lu X, Liu Z. Epidemiology of haemodialysis catheter complications: a survey of 865 dialysis patients from 14 haemodialysis centres in Henan province in China. *BMJ Open* 2015;5:e007136.
- Mendu ML, May MF, Kaze AD, Graham DA, Cui S, Chen ME, *et al.* Non-tunneled versus tunneled dialysis catheters for acute kidney injury requiring renal replacement therapy: a prospective cohort study. *BMC Nephrol* 2017;18:351.
- Matsunami M, Nakamura Y, Tanaka K, *et al.* The use of a tunneled permanent catheter as temporary vascular access in arteriovenous graft patients for long-term patency. *Ren Replace Ther* 2019;5:40.
- Nasiri E, Rafiei MH, Mortazavi Y, Tayebi P, Bariki MG. Causes and Risk Factors of Hemodialysis Catheter Infection in Dialysis Patients: A Prospective Study. *Nephrourol Mon* 2022;14:e117820.
- Aydin Z, Gursu M, Uzun S, Karadag S, Tatli E, Sumnu A, *et al.* Placement of hemodialysis catheters with a technical, functional, and anatomical viewpoint. *Int J Nephrol* 2012;2012:302826.
- Naumovic RT, Jovanovic DB, Djukanovic LJ. Temporary vascular catheters for hemodialysis: a 3-year prospective study. *Int J Artif Organs* 2004;27:848-54.
- Yousefi H, Hosseini M, Falaki M, Noghbi FA, Samimaghani H, Yousefi M, *et al.* Durability of the two-lumen catheter in hemodialysis patients; Ethanol 70%-heparin versus cefazolin-heparin: a randomized, double-blind clinical trial study. *J Nephropharmacol* 2023;12:1-5.
- Clark EG, Barsuk JH. Temporary hemodialysis catheters: recent advances. *Kidney Int* 2014;86:888-95.

14. Western Australian Department of Health. Department of Health Engagement Suite: Framework. Perth: Health Networks, Western Australian Department of Health; 2017.
15. Aubaniac R. Subclavian intravenous injection; advantages and technique. *Presse Med* (1893) 1952;60:1456. [French].
16. Salgado OJ. Vascular Access for Hemodialysis - Overview and Emphasis on Complications. Hemodialysis. InTech; 2013. Available from: [cited 2023, Aug 1].
17. Seldinger SI. Catheter replacement of the needle in percutaneous arteriography; a new technique. *Acta Radiol* 1953;39:368–76.
18. Baier C, Linke L, Eder M, Schwab F, Chaberny IF, Vonberg RP, *et al.* Incidence, risk factors and healthcare costs of central line-associated nosocomial bloodstream infections in hematologic and oncologic patients. *PLoS One* 2020;15:e0227772.
19. Jarraya A, Kammoun M, Chtourou A. Complications and its risk factors of percutaneous subclavian vein catheters in pediatric patients: enhancing the outcomes of a university hospital in a low-income and middle-income country. *World Journal of Pediatric Surgery* 2023;6:000523.
20. Samaha D, Clark EG. Common errors in temporary hemodialysis catheter insertion. *Semin Dial* 2019;32:411–6.
21. Chua HR, Schneider AG, Sherry NL, Lotfy N, Chan MJ, Galtieri J, *et al.* Initial and extended use of femoral versus nonfemoral double-lumen vascular catheters and catheter-related infection during continuous renal replacement therapy. *Am J Kidney Dis* 2014;64:909–17.
22. Dugué AE, Levesque SP, Fischer MO, Souweine B, Mira JP, Megarbane B, *et al.*; Cathedia Study Group. Vascular access sites for acute renal replacement in intensive care units. *Clin J Am Soc Nephrol* 2012;7:70–7.

Conflicts of interest

The authors certify that there is no conflict of interest with any financial organization regarding the material discussed in the manuscript.

Authors' contributions

I Gusti Putra: conception and design, drafting of the article and collection and assembly of data; Heroe Soebroto: critical revision of the article for important intellectual content and final approval of the article; Yan E. Sembiring: provision of study materials or patients; Danang H. Limanto: statistical expertise and critical revision of the article for important intellectual content; Arief R. Hakim role: conception and design, Pande A. Permatananda: analysis and interpretation of the data; Jeffrey J. Dillon: conception and design; Cheong Lim: conception and design. All authors read and approved the final version of the manuscript.

History

Manuscript accepted: July 18, 2023. - Manuscript received: July 14, 2023.

the longevity of temporary hemodialysis catheters by insertion site in patients undergoing hemodialysis: systematic review

ORIGINALITY REPORT

1 %

SIMILARITY INDEX

0%

INTERNET SOURCES

1%

PUBLICATIONS

0%

STUDENT PAPERS

MATCH ALL SOURCES (ONLY SELECTED SOURCE PRINTED)

1%

★ www.balimedicaljournal.org

Internet Source

Exclude quotes On

Exclude bibliography On

Exclude matches < 1%